

Section 5

Technical information

- Assessment templates
 - On-Farm Assessment
 - Farm Assessment for Stock
- Post Mortem and tissue sampling techniques
- How to remove a brain
- Sampling aqueous and vitreous humour
- Humane Euthanasia
- Body Condition Scoring



ON-FARM ASSESSMENT

Date:	Address:
Farm Name:	
Owner:	
Sharemilker:	Runoff:
Manager:	Ph Nos:
Employees:	
HEALTH (incl deaths):	
FEED & BCS:	
INFRASTRUCTURE:	
ANIMAL HUSBANDRY:	
CLIMATE:	

YOUNG STOCK:

RECORDS:

PEOPLE:

FINANCE:

OTHER NOTES:

FARM ASSESSMENT FOR STOCK

Date:	_____	Address:	_____
Farm Name:	_____		_____
Owner:	_____		_____
Sharemilker:	_____	Runoff:	_____
Manager:	_____	Ph No's:	_____
Employee(s):	_____		_____
	_____		_____
	_____		_____

Farm and Stock Reconciliation

PSM:	PSC:	Farm Map	Y	N
Breed Cows:	Breed Sheep:	YS Grazing	ON	OFF

	June	October	Sales	Deaths	Now	
M/A Cows						No's Milked
R2 heifers						No's In Pennos
R1 Heifers						RFM
Bulls						Lame
MA Ewes						Mastitis
Two teeths						Colostrums
Hoggets						Springers
Lambs						No's Dry
Rams						
Others						
Others						

MS Total	_____	MS/Cow	_____	MS/ha	_____
Lambs Sold	_____	Finished	_____	Store	_____
Stock Sold	_____	Weaners	_____	Store	_____

Farm Area (eff. Ha)	
Block 1	_____
Block 2	_____
Block 3	_____
Runoff 1	_____
Runoff 2	_____

Finished	_____
----------	-------

Comments/Observations:

Feed Management Parameters

	1	2	3	4	5	6	7
Block/Mob							
Average Pasture covers							
Pre grazing covers							
Post grazing residuals							
Growth rate							
Wedge	+ / -	+ / -	+ / -	+ / -	+ / -	+ / -	+ / -
Area/day & Round length							
Intakes/cow/day							

Supplements fed KgDM/cow/day

Supplements on hand

Hay
Silage
PKE
Crop
Nitrogen (rate/area)

1	2	3

1	2	3

Farm Consultant

Feed Budget:

Y

N

Feed Comments & Observations:

Weights and BCS

Young stock	Weights kg					
Weaning						
6 Months						
9 Months						
12 Months						
15 Months						
18 Months						
21 Months						
24 Months						
Weight/BCS Comments:						
Time in the farming cycle:						

Mob 1

BCS %

<3.0	<3.5	<4.0	<4.5	<5.0	5.0>

Mob 2

BCS %

<3.0	<3.5	<4.0	<4.5	<5.0	5.0>

Mob 3

BCS %

<3.0	<3.5	<4.0	<4.5	<5.0	5.0>

Animal Health Parameters

Calving

RFMs
Down cows
Paralysis
Inductions
No's calved
No's mated

Observations:

Lameness

1
2
3
4
5

Observations:

Mastitis

Incidence
Single/Multi 1/4
Repeats

Observations:

MT

Rate

Calving records
AI mating records
Natural Mating records
Animal Health records
Certificates

+ / -
+ / -
+ / -
+ / -
+ / -

Magnesium

Calcium

Minerals

Zinc

Teat spray

+ / -
+ / -
+ / -
+ / -
+ / -

Painful Husbandry Procedures

Calf dehorning
Dehorning > 9mths
Castration > 6mths
Tail docking

+ / -
+ / -
+ / -
+ / -

Animal Health Comments:

Climate

Features:

Winter	Spring	Summer	Autumn

During assessment:

Infrastructure

Cowshed:

Water:

Feed Pad (size, area, troughs):

Races:

Calf rearing:

Housing:

Bobby Calves:

Fences:

Machinery:

Management/Comments

Observed animal husbandry skills of labour:

Financial:

Attitude of management:

Other compliance issues (e.g. effluent, tagging):

Assistance required:

Notes

Summary

	No Risk	Low Risk	High Risk		Scale	Severity	Capability
Feed					1 2 3	1 2 3	1 2 3
BCS					1 2 3	1 2 3	1 2 3
Youngstock					1 2 3	1 2 3	1 2 3
Health					1 2 3	1 2 3	1 2 3
Climate					1 2 3	1 2 3	1 2 3
Infrastructure					1 2 3	1 2 3	1 2 3
People					1 2 3	1 2 3	1 2 3
Finance					1 2 3	1 2 3	1 2 3

Post Mortem guidance

POST MORTEM AND TISSUE SAMPLING TECHNIQUES FOR INVESTIGATING EMACIATION AND ILLTHRIFT IN RUMINANTS WHERE NEGLECT IS SUSPECTED

Notes prepared by Fraser Hill, BVSc, FACVSc, Veterinary Pathologist, Gribbles Veterinary Pathology, Palmerston North

INTRODUCTION

When requested to investigate neglected, starving or diseased animals it is important to perform thorough investigations and collect appropriate samples in a methodical way.

These procedures detail samples to collect for laboratory investigation and presume clinical examinations, animal identification, condition scoring, bodyweight, description of lesions, and photographs of animals have been carried out.

All samples collected need to be clearly identified so a chain of evidence can be established.

The most important details to establish in cases of starvation or emaciation are the levels of adipose tissue reserves remaining. Serous atrophy of fat occurs when lipid mobilisation from body fat reserves is excessive and extended over long periods of time. It is commonly seen in the coronary groove of the heart and the bone marrow of chronically ill and starving animals.

Atrophic fat reserves become watery and translucent (gelatinous), as a result of lipid depletion and an increase in the glycosaminoglycan content of the interstitium secreted by proliferating mesenchymal cells.

Fat mobilisation is a reflection of dietary energy deficit in animals with adequate fat reserves that are starved (inadequate caloric intake) or suffering from diseases that produce malabsorption or protein loss.

Fat reserves are found on the heart, in the mesentery around the kidneys, in the deep layers of the skin, and in the bone marrow, where on average 50% of the tissue is fat.

With regard to chronic malnutrition; if the diet does not contain sufficient amounts of energy or protein to meet requirements, animals will metabolise stored fat and protein to meet demands for normal biological body functions. Therefore the fat depots, depending on requirements, will gradually become depleted and eventually show the characteristic signs of serous atrophy.

The body's fat depots are affected by chronic malnutrition. The subcutaneous fat disappears first; whereas fat stores associated with vital organs such as heart, liver and kidney are relatively stable and only become depleted after prolonged malnutrition.

Fat depots behind the eyes and in bone marrow are very stable and only become depleted after severe malnutrition.

Initially the animal's metabolism will adapt to cope with malnutrition by lowering physical activity and reducing protein turnover. In the long run the homeostatic mechanisms cannot compensate entirely for the imposed deficiencies of protein and energy, and body fat reserves from the stable depots behind the eyes and in bone marrow are also utilised.

The time frame of events varies according to the animal's condition at the onset of the nutrient deficient period, requirements during the period, e.g. young, growing and adult pregnant animals require a relatively high protein-energy intake and to the quality and quantity of feed which is available.

The development of serous atrophy may take weeks, or even months rather than days depending on these factors.

Parasitism, including liver parasitism (liver fluke) is likely to exacerbate the effects of malnutrition to an extent that will depend on the degree of infestation.

Other chronic diseases including tuberculosis, paratuberculosis, actinobacillosis, and actinomycosis may result in inappetence, ill-thrift and emaciation and hence lead to the development of serous atrophy. Therefore, a thorough necropsy to rule out disease is required before making a diagnosis of starvation.

Photographs should be taken of any gross pathology found during the necropsy.

SAMPLES TO COLLECT IN THE LIVE ANIMAL

If animals are still alive, collect serum and whole blood samples into plain and EDTA tubes. Affected animals and other animals to a minimum of 10 should be sampled. Trace element, serology (BVD, liver fluke, Johnes), haematology and biochemistry testing can be carried out on these samples.

Faecal samples should be collected from 10 animals so faecal egg counts for nematode parasites can be undertaken. All samples should be individually labelled with the animal's tag number or identifying features.

SAMPLES TO COLLECT FROM THE ENVIRONMENT

The paddocks and surrounding environment animals could have access to should be searched and examined. Any potential toxic materials, or plants the animals could have accessed should be sampled. Powders, residues, suspicious metals eg lead or zinc, should be sampled into a labelled screw top container. Any unidentified plants animals could have been grazing should be sampled and representative sections of leaves, stems and flowers collected into labelled paper bags for identification, or dried for later identification. Consider seasonal toxic plants such as acorns from oak trees and note their presence or absence.

MORIBUND LIVE ANIMALS

EUTHANASIA METHODS

Techniques for euthanasia include the appropriate dose of pentobarbitone, xylazine anaesthesia followed by rapid infusion of a saturated solution of MgSO_4 or KCl 100ml/45kg (1 litre/450kg cow) or shooting. If pentobarbitone is administered the carcass must be disposed of so scavenging or feeding cannot occur. If MgSO_4 or KCl are administered the carcass can be used for pet food but not human consumption as xylazine has been used. A small study using a .22 calibre rifle aimed into the frontal cortex only has proved successfully at killing cattle and sheep without damage to the critical mid and hindbrain sites examined for transmissible spongiform encephalopathy exclusion. The angle of shooting is critical so the bullet is not aimed towards the foramen magnum.

DEAD ANIMALS

If the animal has been dead less than 24 hours, and the conditions are favourable, proceed to necropsy. If the time of death is unknown or the animal is obviously autolysed consider a modified examination possibly collecting only vitreous humour or bone marrow fat. Rumen content could be inspected for obvious toxic agents. Tissues for histopathology or microbiology are probably unsuitable, but it is probably better to collect and store them, even if they ultimately can't be used.

Appendix 1: CHECK LIST OF SAMPLES TO COLLECT

Live animals

Sample	Collection container	Number	Tests
Serum	Plain (red) vacutainer	All sick animals or sick animals + others to a minimum of 10	Serology Biochemistry Trace elements
Whole Blood	EDTA (purple)	All sick animals or sick animals + others to a minimum of 10	Haematology
Faeces	Pottle	10	Parasitology

Environment

Sample	Collection container	Number	Tests
Plants	Paper bags	Any suspicious or grazed plants	Identification
Potential toxins	Labelled screw top pottles	Any found	Visual or chemical identification
Supplementary feed	Sealed bag	Samples from various sites within storage shed	Visual or chemical identification

Dead animals

Sample	Collection container	Number	Tests
Fixed liver, kidney, heart, spleen, lung, jejunum, ileum, colon, lymph node, bone marrow, brain. Any lesion	Labelled screw top pottle containing 10% buffered formalin	1 of each	Histopathology
Fresh liver	Labelled screw top pottle	1	Microbiology, trace elements, toxicology
Fresh lung	Labelled screw top pottle	1	Microbiology
Rumen contents	Labelled screw top pottle	1	Toxicology
Plants or debris in rumen	Labelled screw top pottle	1	Identification

Appendix 2:

NECROPSY TECHNIQUE

- All animals are placed on their left side with the dissector facing the animal's abdomen.
- Use at least ten times the volume of 10 percent buffered formalin to the volume of tissue taken for histopathology.
- After fixation it may now be sent with minimal fluid or just formalin soaked cotton to keep it moist.
- Routinely take tissue samples of liver, kidney, lung, heart, bone marrow, spleen, rumen, abomasum, small intestine (duodenum, jejunum and terminal ileum), large intestine and all lesions.
- Sections should be no more than 1 cm thick.
- Do not scrape or squeeze section to be taken for histological examination.
- Always take sections with a sharp knife, never with a pair of scissors.
- When taking sections from paired organs, make the left side pieces longer or larger (not thicker).
- Brain should be collected from animals with a history of neurological disease or when no cause of death is found at necropsy.
- Use of the carcass itself as a cutting board is recommended to prevent dulling the knife.
- To prevent cutting hair and thereby dulling the knife, a stab wound in the axilla is the only time the knife cuts hair.

EXTERNAL EXAMINATION

Following external examination including natural orifices, eyes, and limb and joint palpation, the lymph nodes, nerves, and most vessels are examined when exposed.

NECROPSY

- After an initial stab incision into right axilla, extend skin incision cranially to chin and caudally to perineum.
- Reflect skin on right side and completely abduct right limbs by cutting muscular attachments of scapula and freeing femoral head.
- Reflect mammae or free each testicle separately.
- Incise along costal arch and dorsal flank down and across pelvic rim.
- Reflect this flap and examine abdominal cavity.
- Stab diaphragm near sternum and note inrush or absence thereof of air as lungs collapse. Remove ribs by cutting with rib cutters or saw, first close to sternum, then several cm from vertebrae.
- Check presence and position of all organs.
- Before any visceral organs are removed from the peritoneal cavity, abnormal vessels (shunts) to or from the liver or intestine and especially leading to the caudal vena cava are looked for.
- Free a central rib by cutting off adjacent soft tissue close to bone.
- Check costochondral junction of young animals by cutting along the thin edge cranially or caudally and not the flat medial (pleural) or flat lateral surface.
- Break or attempt to break rib against curvature for test of general bone strength.

ABDOMINAL CAVITY EXAMINATION

- Make several inspection slices into spleen.
- Remove liver leaving diaphragm in place. Incise and inspect gall bladder in appropriate species. Make multiple inspection slices into liver and incise major vessels.
- Remove kidneys separately after examination of adrenals.
- The adrenal glands are usually to be found in most species just in front of the kidneys or just medially to the cranial poles of each kidney.
- Do not hold adrenal itself. Incise adrenal. Note cortex:medulla:cortex (CMC) ratio. Roughly 1:2:1.

- Cut each kidney longitudinally to pelvis. Peel away capsule. Take tissue cross section to include cortex, medulla, and pelvis epithelium.

PELVIS EXAMINATION

- Open bladder to the urethra.
- Cut ovaries longitudinally then transversely.
- Open both horns of uterus, then cervix and vagina.

GASTROINTESTINAL TRACT

- Lay G.I. tract in relative order to be opened as last major procedure of necropsy to prevent faecal contamination of tissues and instruments, unless investigating calf diarrhoea.
- To check G.I. tract, cut along greater curvature of stomach, forestomach, and representative lengths of duodenum, jejunum, and ileum. Open ileocecal orifice and cecum, large and small colon and rectum. Incise major vessels when exposed.

ORAL CAVITY

- To remove the tongue, cervical and thoracic viscera en masse, cut on medial side of both mandibles close to bone and split the symphysis with cutters.
- Pull tongue down and back. Cut through prominent joint of hyoid bones on both sides. Continue down the neck removing trachea and oesophagus, and examining the jugular veins.

THORAX

- Transect aorta and vena cava at the diaphragm after cutting the pluck and aorta away from the vertebral bodies.
- Examine tongue by transverse sections. Observe and incise thyroids. Observe parathyroids. Cut down full length of oesophagus.
- Check major vessels then cut heart free from pluck at the base.
- Palpate lungs softly. Cut down trachea and major bronchi and observe cut ends of pulmonary arteries for emboli, bronchi for parasites.

LUNG

- If it is not firm, it is probably not pneumonia.
- There is no such thing as pulmonary congestion and oedema without a cause, i.e. – if you can't find a good reason for it, then it is probably just terminal artifact.
- The key is palpation.

HEART

- To examine the heart cut in the same direction of blood flow.
- Open right atrium.
- Check right atrioventricular valve, orifices of cranial vena cava, caudal vena cava, ovalis, and coronary sinus.
- Open right ventricle. Extend incision up pulmonary artery, open pulmonary trunk past bifurcation. Check semilunar valves.
- Open left atrium and ventricle with straight incision. Incise through parietal cusp of left atrioventricular valve.
- Check left atrioventricular valve and openings to pulmonary veins.
- To open aorta, insert knife under septal cusp of left atrioventricular valve. Incise through wall of atrium, out and down aorta.
- Check semilunar valves or aorta, orifices and right and left coronary arteries, orifice of brachiocephalic trunk.

JOINTS

A quick check of joints is recommended. Hip has already been opened and checked. Then, stifle, shoulder, atlanto-occipital (when head removed).

EYE AND BRAIN

- Move head to locate joint. Obtain CSF at this time if required from dorsal or ventral approach. Cut all soft tissues around joint. Insert knife into joint and transect spinal cord and ligaments of joint and transect spinal cord and ligaments of joint dorsally and ventrally. Remove head. Skin rest of head.
- To remove eye: Grasp, with minimum traction, the skin around eye. With belly of knife, cut soft but tough tissues around orbit.
- Cut deeply around orbit, staying close to the bone. Transect optic nerve.
- Remove eye leaving the optic nerve longer on the left eye for easy identification.
- If aqueous or vitreous humour because hypomagnesaemia or nitrate poisoning is suspected, collect now. If the time since death is known and likely to be less than 24 hours collect aqueous humour. Using a 18G, 25 mm needle on a 5 ml syringe, gently insert the point of the needle through the cornea and aspirate 0.5-1ml of fluid. If the time since death is not known then collect vitreous humour. Insert the needle through the sclera, and uvea into the vitreous behind the eye. Aspirate gently to obtain 0.5-1 ml of fluid. If the sample is contaminated with blood, discard it and collect from the other eye.
- For proper fixation, fix the globe, free of surrounding tissue, in toto.
- Remove major muscle masses. Look into foramen magnum to note the normal absence of the cerebellar vermis. Suspect a brain lesion if it is seen (prolapsed).
- Hold head with thumb in eye socket, index finger on top of blade of saw. One cut is transverse through the frontal bone caudal to zygomatic process of frontal bone.
- Place head on right side. Another cut is sagittal, just medial to left occipital condyle.
- Place head on left side for next cut. Cranial part of head is toward you, thumb in eye socket, fingers around mandible. Link cuts with 2 more longitudinal cuts.
- Pry up skull cap. Best to use a screw driver to avoid damaging knife.
- With head in upright position, tap it lightly on table to loosen brain.
- Cut olfactory peduncles, internal carotid arteries, and cranial nerves as brain is removed. Tilt head so that the brain will rest on table.
- To remove pituitary: Pick up dura from basilar part of occipital bone between the sawn condyles after cutting the dura on both sides of the gland back to the foramen. Peel it forward to include pituitary.
- Cut pituitary transversely.

BONE MARROW

To make a bone marrow impression smear or obtain a section of marrow, crack open almost any large bone of young animals or the ends of long bone in mature animals by using the rib cutters to obliquely crack the bone. Cores can be put in formalin for fixation.

THE DESCRIPTION

Gross post mortem descriptions have their own vocabulary. If the 7 broad categories listed are used with each lesion an accurate description can be derived. Examples of adjectives and ways of describing are included.

LOCATION:

Where on the skin, what part of the lung, etc? The anatomical position, and its relationship to other organs and tissues (cranial, caudal, dorsal, ventral, left side, stomach, right adrenal). A quick sketch may be of value here.

COLOUR:

Use of the primary colours is best with shades and degrees as needed. Dark, brilliant, light, mottled, streaked, or stippled may apply.

SIZE:

Only metric units should be used. Your necropsy knife handle could be marked every cm so you have an instantly available measuring device.

SHAPE:

Use descriptive terms such as ovoid, round, conical, flat, nodular, lobular, tortuous, discoid, punctuate, bulbous, wedge-shaped, fusiform, laminated, clustered, lace-like, straight-edged, etc.

CONSISTENCY AND TEXTURE:

A most important feature of lungs; palpation is the key. Sometimes even physical manipulation, such as actual bone breaking at the necropsy table, is helpful. Soft (lips), firm (nose), and hard (forehead) as well as fluctuant, gas filled, friable, viscous, mucoid, gelatinous, stringy, turgid, dry, inspissated, caseous, crepitant, adhesive, gritty, granular, pliable, homogenous, etc. may be used.

NUMBER AND EXTENT (%):

Give a count whenever possible. Use dozens or hundreds in cases that apply. In cases of pneumonia, liver disease, or where portions of a large organ are affected, the extent of involvement is given in percent.

CONTENT:

Quantity and nature of content in any cavity, natural or pathological, is described in volumetric terms as well as the colour, odour, consistency and shape of the content itself. Stricture or collapse of the gut or uterus may require such terms as patent, dilated, partially obstructed, obliterated, narrowed (including degree of narrowing), branched, communicating, tortuous, etc. with respect to their lumen.

ADDITIONAL DESCRIPTORS

In addition to the above standard set of features noted about each lesion, the necropsy report could also include comments on.

ODOUR:

This is one of the hardest features to evaluate, but it is often quite diagnostic and by necessity is described in relation to well-known odours. For example, similar to rancid butter, cider, onions, etc.

DISTRIBUTION AND SURFACE APPEARANCE:

Focal or multi focal, locally extensive, or diffuse covers many conditions while total, scattered, streaked, and laminated are useful. Ulcerated, hairy, smooth, depressed, irregular, eroded, pitted, elevated, glistening, dull, scaly, membranous are of much value for surface descriptions.

NEOPLASIA:

Certain tumours can be presumptively diagnosed grossly, because of the animal's history or experience, but a mass by itself could be one of several conditions. Lymphosarcoma can mimic almost any condition, grossly and can occur in any age animal (even aborted fetuses) and tissues (eg heart, lung) instead of the expected lymphoid areas. Without evidence of prior damage in an organ, such as the liver or thyroid, multiple lumps probably represent neoplasia and not compensatory hyperplasia or regeneration.

THE TIME OF DEATH:

Death is the culmination of dying, but to establish the exact time is often difficult. A few generalities can be used.

Rigour mortis, the stiffening of death, is the best related to the body temperature and the metabolic activity at the time of death. Rigour mortis occurs rapidly in animals that are excited or severely stressed just before death. The opposite is true for animals that are moribund or cachectic for a long period before death. In these latter cases, rigour may not occur for hours, if it occurs at all, and when it does, it may not be complete or easily noticeable. The length of time a body is in rigour is directly related to the onset, as is

the post rigour relaxation time. An animal that takes minutes to go into rigour will only have a short period of rigour. The jaw muscles of dogs and most animals are the first to set up in rigour followed by the eyelids, tail, digits, distal limb muscles, and finally the larger limb muscles. They relax in a similar sequence. Once rigour has been broken by moving the body or limb, the rigour will not return.

Algor mortis, the cooling of the carcass with death, is another useful but not absolute parameter to be noted. Rectal, oral, axillary, or even deep muscle, abdominal, or heart blood temperature are at best only suggestive as they vary so widely after death. Ambient temperature is important in its interpretation. When a heavily-wooled sheep is put in the necropsy refrigerator or left out in freezing weather, its body temperature will increase for hours because of insulation afforded by the wool and the heat produced by continued fermentation in the gastrointestinal tract.

Clouding of the lens of most species is quite variable and the most apropos comment to make here is that the lens clouds easily when cold. Such cloudiness is often mistaken for cataracts. To differentiate from true cataracts, one has only to warm the head and eyes, and these "cold cataracts" will disappear.

Rumen mucosal sloughing is a difficult evaluation as it can begin within twenty minutes in the "normal cow." This usually takes several hours however.

Blood glucose drops rapidly about 20 minutes after death while some other biochemical values, such as calcium or other blood minerals, may not decrease over much longer periods. Comparison with C.S.F. values may be helpful for some. On the other hand, the continued plateau of glucose levels may indicate a poisoning by sodium fluoroacetate which prevents glucose's enzymatic breakdown. Blood urea nitrogen (BUN) does not increase after death as many believe, but instead plateaus for up to 3-4 hours before gradually decreasing.

Food digestion: Animals removed from their normal habitat just after eating may not have any appreciable digestion noted of their stomach contents if they are severely stressed for 24 to 48 hours or more after being moved.

Developmental stages of identifiable eggs or maggots on a flyblown carcass may indicate when the wound or carcass became flyblown and may thus be an indication of time of death.

Although not related to time of death, one rather unique way to slow down decomposition is to bury the carcass in the cool earth. This will often delay autolysis, considerably, if other means of preservation is available.

DECOMPOSITION:

Fat animals or fully fleeced animals actually increase in body temperature when placed in a refrigerator after death. A blanket, like wool or long hair, is a great insulator, keeping cold out and heat in.

Acknowledgements: These notes are taken fully or in part from *The Necropsy Book* by John M King and advice of Keith McSporran, Gribbles Veterinary Pathology, Auckland.

“HOW TO” REMOVE A BRAIN

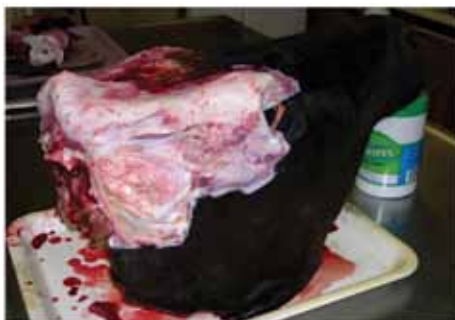These instructions apply to removal of brains from all species of animals. They have been provided by Gribbles Veterinary.

Supplies required:

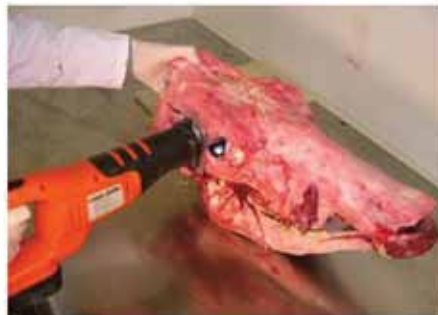- reciprocating saw or good quality meat saw
- screwdriver
- knife or scissors
- formalin
- bucket
- sample containers

Method:

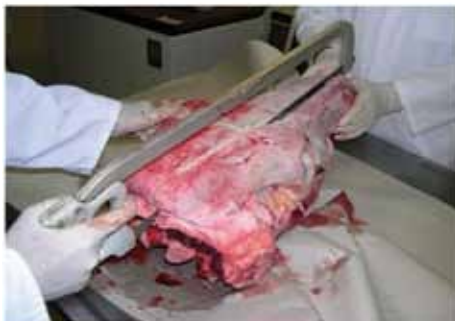1. Euthanase the animal using Pentobarbitone or Xylazine sedation (followed by rapid infusion of saturated solution of MgSO₄ or KCl 100mL/45kg) or by shooting with a .22 calibre rifle aimed into the frontal cortex only, vertical not towards foramen magnum.
2. Remove the head, skin the caudal portion and remove the ears.
3. Collect spinal cord from the carcass by grasping the spinal cord with forceps. Pull cord cranially, cut 2 cm of cord free with knife or scissors, then place in a sample container and keep fresh (this can also be frozen).
4. Make saw cuts in skull –
 - a. transverse cut behind eyes to below the centre line of the eye
 - b. intersect the middle of transverse cut with the lateral aspect of the poll on both sides
 - c. sagittal cut medial to occipital condyle, from foramen deep into nuchal eminence.



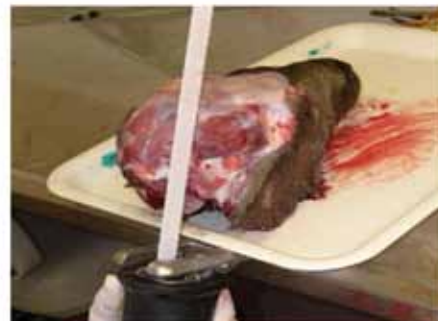2. Remove skin and ears from head



4a. Transverse saw cut

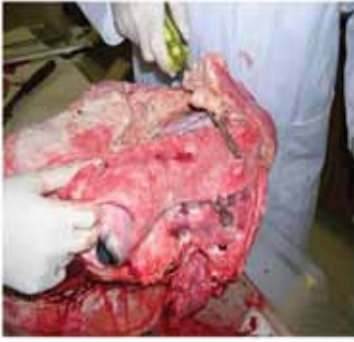

4b. Intersecting cut

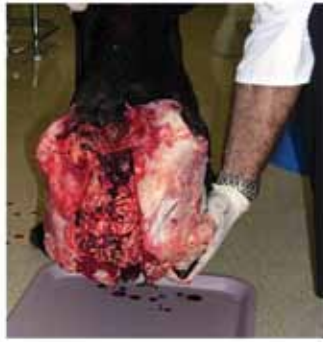

4c. Sagittal cut

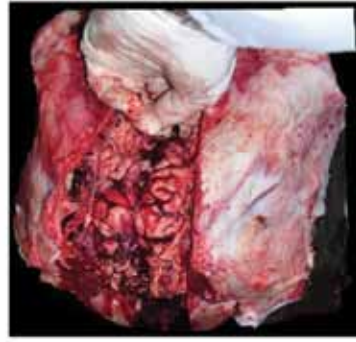Tips – if an assistant is available, get them to hold the head whilst sawing and/or put the nose into a bucket to stabilise. Using a reciprocal saw is much easier and quicker.



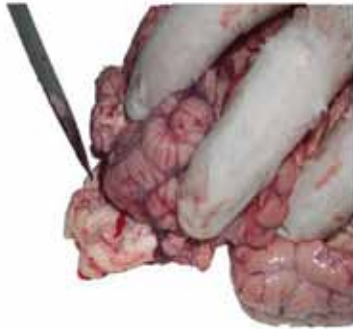5a. Level cut bone free



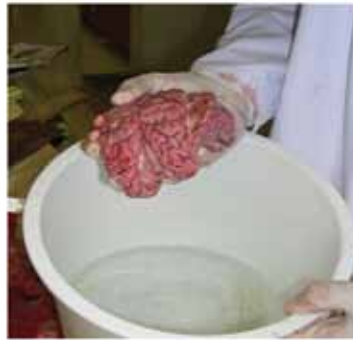5b. Tap head to dislodge brain



5c. Remove brain



5d. Include the obex (at knife point)



6. Place brain in formalin to fix

5. Remove the brain –

- a. Lever the cut bone free using a screwdriver rather than a knife
- b. Tap head (condyles) firmly on a hard surface so the brain slumps free
- c. Cut away the meninges, roll brain out starting at olfactory lobes, sever internal carotid arteries and cranial nerves as brain is removed
- d. The obex must be included as it is a critical area to examine histologically.

6. Place the brain in formalin (10 times the brain's volume) to fix.

7. Submit fixed brain and fresh spinal cord for testing.

Tip – fix the brain in a bucket of formalin (10 times volume of brain) and then transfer to a smaller container or plastic bag to submit.

Note: the heads shown in the above diagrams are fully skinned (as were sourced from a meat processing plant) – this isn't necessary for routine brain removal.

SAMPLING AQUEOUS AND VITREOUS HUMOUR

Fraser Hill BVSc, FACVs, Veterinary Pathologist, Gribbles Veterinary Pathology, Palmerston North

A useful sample to collect when investigating sudden death in cattle or sheep is ocular fluid. Rather than using a syringe and needle, use a vacutainer to aspirate the fluid (figure 1).

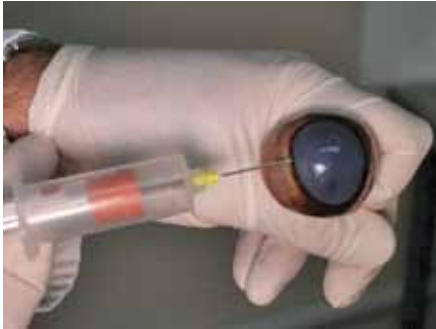

Figure 1

Insert vacutainer needle through the limbus.

If the time since death is known and likely to be less than 24 hours collect aqueous humour. Insert the needle through the limbus and angle towards the cornea keeping the point in front of the lens (figure 2). Once the tip is free in the aqueous push the vacutainer onto the needle. Aspirate 0.5–1 ml of fluid.

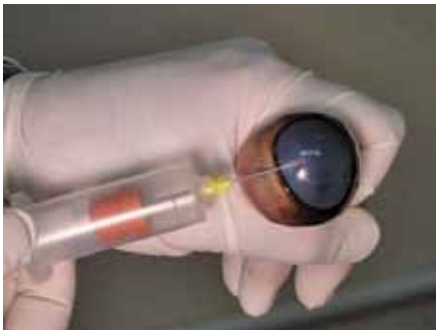


Figure 2

To collect aqueous humour aim the tip of the needle into the aqueous in front of the lens

If the time since death is not known then collect vitreous humour. Insert the needle through the limbus and uvea into the vitreous behind the lens (figure 3).

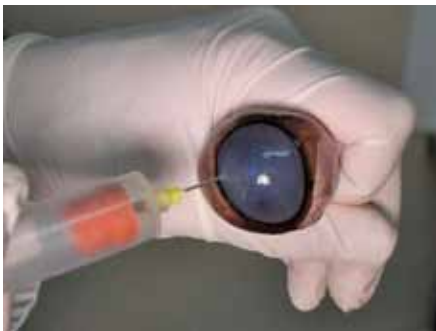


Figure 3

To collect vitreous humour aim the tip of the needle into the vitreous behind the lens

As vitreous humour is thicker, a syringe and needle may be required to successfully retrieve a sample (figure 4).

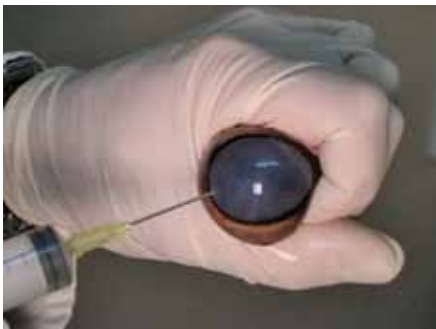


Figure 4

Use a syringe and needle to collect vitreous humour if the vacutainer technique is unsuccessful

If the sample is contaminated with blood, discard it and collect from the other eye.

This technique can be carried out while the eyeball is still in the carcass.

Euthanasia

HUMANE EUTHANASIA

The overriding consideration during emergency slaughter is to prevent the animal from suffering further pain or distress. Humane slaughter depends on rapidly inducing failure of brain function. This can be achieved by causing sufficient brain damage to render the animal insensible and then cutting the major blood vessels of the neck to cause death.

Devices for emergency slaughter should be in good condition (e.g. knives should be sharp) and appropriate for the animal (e.g. captive bolt device cartridge strength or firearm calibre).

Captive bolt firearms, of a suitable design and calibre, should be used to render animals insensible. There are two types of captive bolt firearm – penetrating and non-penetrating. A penetrating captive bolt enters the skull and comes into contact with the brain tissue; a non-penetrating captive bolt employs a ‘mushroom’ percussive head. Both methods provide a concussive blow to the skull, resulting in insensibility because of brain tissue damage, although the damage caused by the penetrating captive bolt will result in less chance of the animal regaining sensibility.

Whenever a firearm is used, it is very important that the operator is competent to use it and takes care to ensure their safety and that of other people and animals.

Free bullet firearms should never be used at point blank range. Instead shotguns and rifles should be used between 5–25 cm from the head.

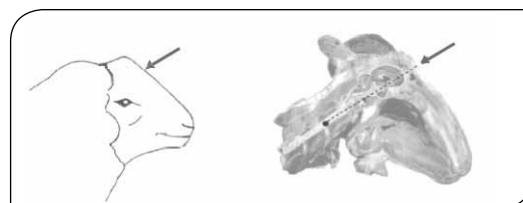
Bleeding an animal should be carried out using a sharp knife with the incision cutting both carotid arteries and jugular veins in one swift stroke. Breaking the neck or severing the spinal cord immediately after cutting the throat only produces paralysis, does not affect the time it takes for the animal to become unconscious, and adds to the potential pain and distress of the procedure.

Sheep

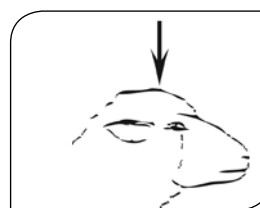Sheep should be rapidly rendered insensible and remain in that state, until death.

The captive bolt firearm must be applied directly against the head of the animal at the position shown below.


The optimal free-bullet firearm position for hornless sheep is on the midline.



The optimum position for captive bolt stunning of hornless sheep is on the highest point of the head, and on the midline, aiming straight down.



The optimum position for heavily horned sheep is behind the poll, aiming towards the angle of the jaw (both free bullet and captive bolt).

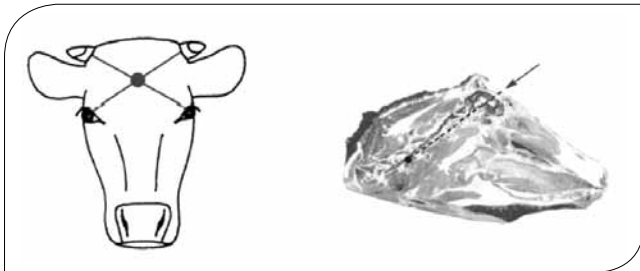


Beef and Dairy Cattle

Shotguns should not be used to destroy adult beef cattle, only calves.

The captive bolt firearm must be applied directly against the head of the animal at the position shown below. The optimum position for beef cattle is at the intersection of two imaginary lines drawn from the rear of the eyes to the opposite horn buds (both free bullet and captive bolt).

Blood supply to the brain in cattle is markedly different from other livestock and this difference can result in prolonged consciousness when only the carotid arteries and jugular veins are severed (the throat cut). Therefore, killing any cattle by cutting the throat may not produce rapid death and therefore is not humane, unless the animal has first been rendered insensible.



Pigs

Pigs up to weaning: a blow to the frontal region of the skull, sufficient to fracture the skull, followed by bleeding out.

Grower, finisher and adult pigs:

- use of a captive bolt pistol, held against the head at the point of intersection of a line between each eye and the opposite ear; or
- shooting with a rifle directed at the same site, but held several centimetres away from the head; or
- shooting with a 12-gauge shotgun, loaded with buckshot, directed behind the ear from a distance of 20 centimetres towards the opposite eye.

Large pigs: the skulls of large pigs are very dense so a captive bolt may not penetrate the skull. A shotgun or rifle is the preferred method.


The correct position of the blow or shot is critical for humane and effective killing. The optimum position for pigs is on the midline just above the eye level, with the shot directed down the line of the spinal cord.



Deer

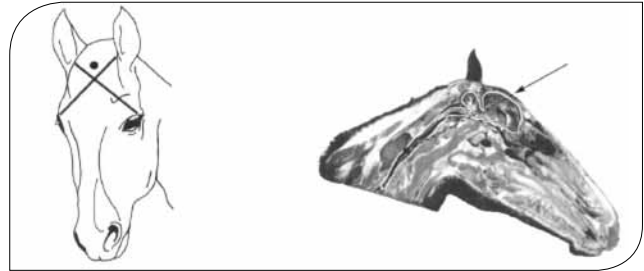
Antlers do not equate to the horns of cattle. The ideal site for bolt or bullet penetrations is in the middle of the forehead, at the crossing point of two imaginary lines drawn from the eyes to the tops of the opposite ears.

In stags this site is found between, sometimes just behind, the antlers.



Equines

The ideal site is slightly above (1cm) the intersection of two imaginary lines drawn from the eye to the opposite ear.

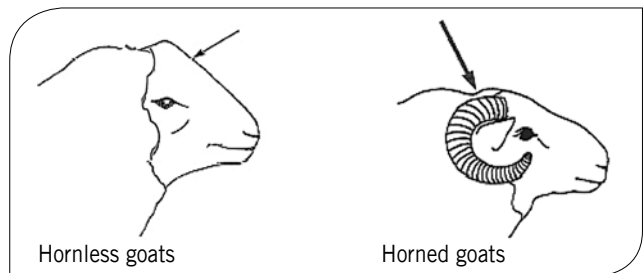


Goats

The correct position and direction of aim are critical for the humane and effective killing of goats and kids.

Hornless goats: The optimum position for hornless goats is on the midline.

Horned goats: The optimum position for horned goats is behind the poll, aiming towards the angle of the jaw.



Body Condition Scoring

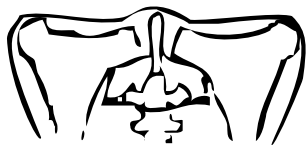BODY CONDITION SCORING

Deer

This chart can be used broadly for all species of New Zealand farmed deer. The use of body condition scoring (BCS) is less accurate for assessing weaner deer.

BCS is based on palpation of the ribs, spine, pelvis and rump of live animals. The simple scoring system varies from score 1 (emaciated) to 5 (excessive condition).

Visual assessment of the body condition of live deer is difficult, particularly during cool months when coat hair is long. A long coat can disguise the actual appearance of the pelvis, ribs and spine, while a short coat can make an animal's appearance irregular and highlight these areas. The only reliable method of assessing live animal body condition is by palpation of the ribs, spine, pelvis and rump.

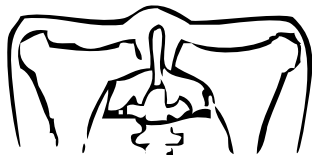

Condition score

Description

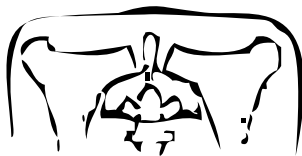1 Emaciated

No fat cover
Pelvis, ribs and spine are prominent
Concave rump area



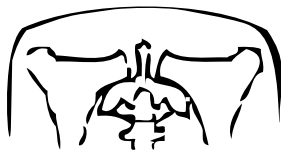
2 Lean

Minimal fat cover
Pelvis, ribs and spine prominent but appear rounded rather than sharp



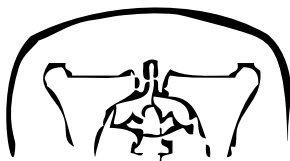3 Good condition

Ideal fat cover
Pelvis, ribs and spine not readily distinguished
Rump area is flat



4 Forward condition

Fat
Pelvis and rump rounded
Spine covered by fat



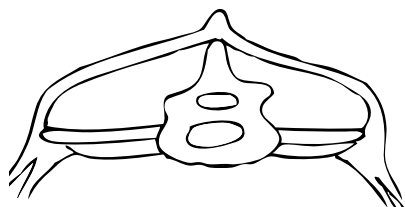
5 Excessive condition

Over fat
Pelvis concealed by fat cover
Rump very convex
Spine hard to palpate

Sheep

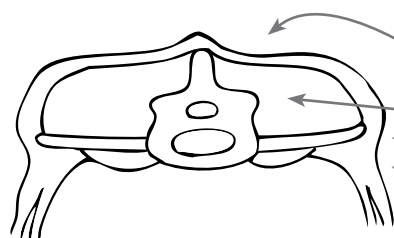
Condition scoring assesses the amount of muscle and fat on the sheep. If there is too much wool on the sheep it is difficult to score body condition accurately by eye. Place the palm of your hand on the lumbar spine (loin) and use fingers on one side and thumb on the other side to feel transverse processes.

Use 0–5 scale to score sheep using the following descriptors:



Emaciated and on the point of death

Condition score = 0



Spine prominent and sharp

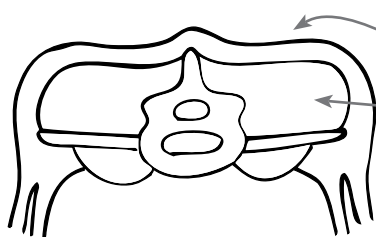
No fat cover

Muscles thin

Horizontal process sharp

Fingers easily pass under

Condition score = 1



Spine prominent and smooth

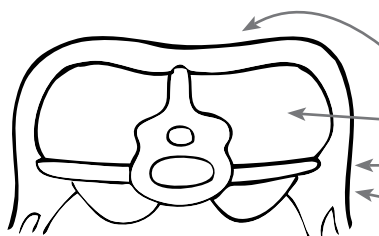
Thin fat cover

Muscles medium depth

Horizontal process rounded

Fingers go under with pressure

Condition score = 2



Spine smooth, rounded

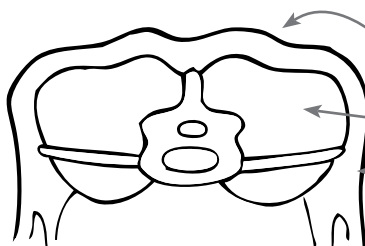
Moderate fat cover

Muscles full

Horizontal process smooth, rounded

Fingers need hard pressure to find ends

Condition score = 3



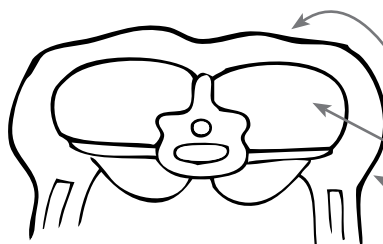
Spine only detected as a line

Fat cover thick

Muscles full

Horizontal process cannot be felt

Condition score = 4



Spine not detectable, fat dimpled over spine

Fat cover dense

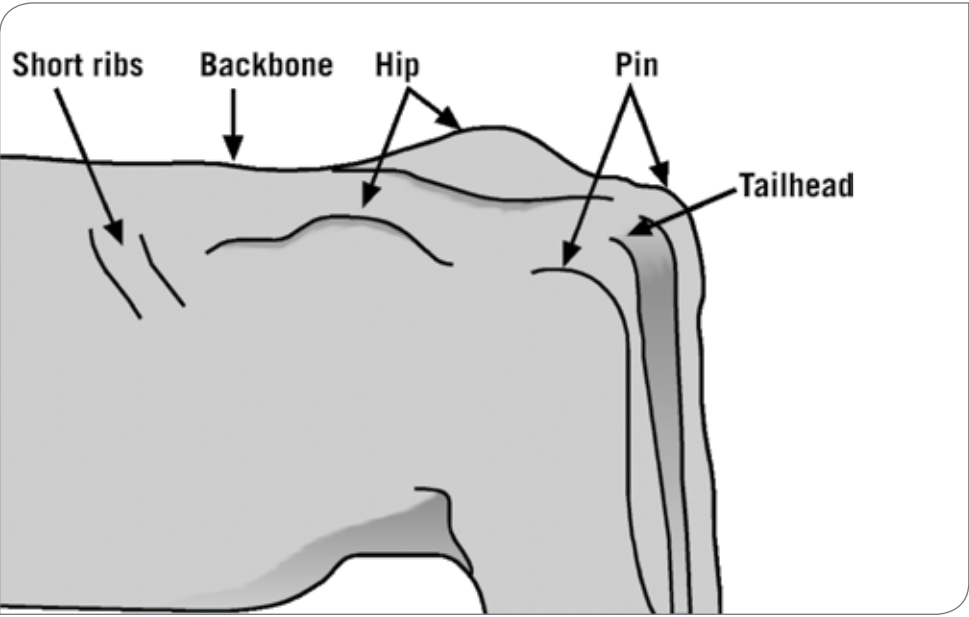
Muscles very full

Horizontal process not detectable

Condition score = 5


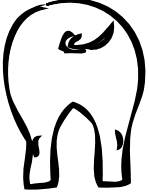



Beef Cattle

The table below provides a guide on how to assess body condition score in beef cows. The condition scoring system is simply based on the amount of fat cover over an animal's bones. Note the focus on observing the rear half of the animal.



Condition Score	Description
0	Emaciated, and on the point of death
1	Very thin with no fat detectable over spine, hips, or ribs. Tailhead and ribs project prominently.
2	Borderline condition, ribs still identifiable but not as sharp to the touch. The spine is still prominent but feels round rather than sharp. Some fat over the hip bones and tailhead.
3	Good overall appearance. Firm pressure must be applied to feel the spine. Fat cover over the ribs feels spongy and areas on either side of the tailhead have fat cover.
4	Good, beef cattle appears fleshy and carries some fat. Spongy fat cover over the ribs and around the tailhead. Fat patches are becoming obvious.
5	Fat. Spine almost impossible to palpate. Large fat deposits over ribs, around tailhead, and below vulva. Bone structure no longer visible.

Pigs

	Condition Score	Pelvic bones, tailhead	Loin	Vertebrae	Ribs
	1	Pelvic bones very prominent. Deep cavity around the tail head.	Loin very narrow. Sharp edges on transverse spinal process. Flank very hollow.	Prominent and sharp throughout the length of the backbone.	Individual ribs very prominent.
	2	Pelvic bones obvious but some slight cover. Cavity around tail head.	Loin narrow. Only very slight cover to edge of transverse spinal process. Flank rather hollow.	Prominent.	Rib cage less apparent. Difficult to see individual ribs.
	3	Pelvic bones covered.	Edge of transverse spinal process covered and rounded.	Visible over the shoulder. Some cover further back.	Covered but can be felt.
	4	Pelvic bones only felt with firm pressure. No cavity around tail.	Edge of transverse spinal processes felt only with firm pressure.	Felt only with firm pressure.	Rib cage not visible. Very difficult to feel any ribs.
	5	Pelvic bones impossible to feel. Root of tail set deep in surrounding fat.	Impossible to feel bones. Flank full and rounded.	Impossible to feel vertebrae.	Not possible to feel ribs.

Dairy Cattle

The table below provides a guide on how to assess body condition score in dairy cattle. Body condition scoring of dairy cows is based on palpation as looks alone can be deceiving. At lower condition scores the weight of assessment is more on the back bone, ribs and short ribs (loin), pin bones and tail head, while at higher scores the assessment also includes the rump and thigh. In assessing body condition score, each point should be assessed individually and then an average score arrived at because different breeds carry their weight on different parts of the body.

When assessing the various parts consider:

- Back bone – is it flat or a ridge, and are the joints easily seen or felt between?
- Ribs and short ribs (loin) – can you see and feel them easily?
- Hip bones – are they flat or pointed?
- Pin bones – are they rounded or pointed and have a tap-like appearance?
- Rump area – is it flat?
- Thigh area – is it depressed or rounded?

For additional guidance see the DairyNZ Body Condition Scoring Reference Guide:

<http://www.dairynz.co.nz/page/pageid/2145864561/Health>

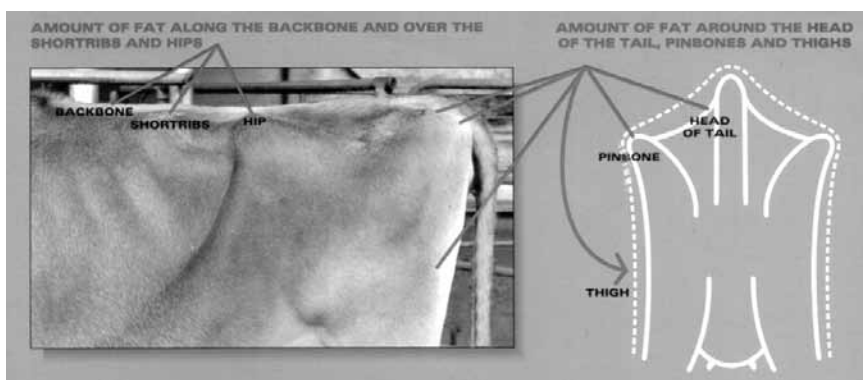


Table of characteristics of points at each score(for each score)

BCS 1		No internal or external fat reserves
BCS 2	Back bone Ribs Short ribs Pins Hip bones Tail-head Rump	Notches distinct, easy to count All easily counted from a distance Very sharp edges Three-pronged tap formation very evident Deep depressions on side of hooks Very prominent, angular and sunken Severe depression
BCS 3	Back bone Ribs Short ribs Pins Hip bones Tail-head Rump Thigh	Prominent and notches distinct Easily seen, no discernable cover Deep indentation and sharp ends Three-prongs discernable but no sharp edges Sharp edges; depression on sides appearing Prominent with a deep V shape Slight depression Indented – no visible fat
BCS 4	Back bone Ribs Short ribs Pins Hip bones Tail-head Rump Thigh	Slightly risen and tops of notches visible Rounded but easily felt Rounded at ends Triangle shape with no sharp edges Depressions in side appearing, no sharp edges Sunken with shallow 'U' shape Slight depression Slight depression
BCS 5	Back bone Ribs Short ribs Pins Hip bones Tail-head Rump Thigh	Smooth Rounded to touch and not individually visible Rounded edges Slightly rounded Rounded Even cover, no sharp edges Flat even cover Smooth and flat
BCS 6	Back bone Ribs Short ribs Tail-head Pins Rump Thigh	Rounded across the loin Rounded and fat cover felt Smooth edges to ends and starting to round Fat cover appearing Fat cover bulging Flat Starting to round
BCS 7	Back bone Tail-head Pins Hip bones Rump Thigh	Flattened out across loin Fat folds appearing either side Not discernable Well rounded and buried in fat Well rounded Rounded outwards with rolls of fat
BCS 8	Ribs Short ribs Hip bones Pins Thigh	Very flat Flat without indentation Flat edges to hooks Large folds of fat on either side Rolls of fat easily felt
BCS 9	Back bone Rump	Buried in fat Fat protruding
BCS 10		Excessive internal and external fat

Locomotion Scoring of Dairy Cattle*



www.nz.availa4.com

Research shows that production suffers with increasing Locomotion scores:

Locomotion Score	Milk Loss
2	1%
3	8%
4	11%
5	34%

*NZ Research on the Link to Milk Production Impact of Locomotion Score. Dr. Robert Terman, University of Wisconsin-Madison. © 2004. All rights reserved. The report for Dairy Insights 2005.

LOCOMOTION SCORE

1

Clinical Description:

NORMAL

Description: Stands and walks normally with a level back. Makes long confident strides.



Back Posture Standing: Flat



Back Posture Walking: Flat

LOCOMOTION SCORE

2

Clinical Description:

MILDLY LAME

Description: Stands with flat back, but arches when walks. Gait is slightly abnormal.



Back Posture Standing: Flat



Back Posture Walking: Arched

LOCOMOTION SCORE

3

Clinical Description:

MODERATELY LAME

Description: Stands and walks with an arched back and short strides with one or more legs. Slight sinking of dew-claws in limb opposite to the affected limb may be evident.



Back Posture Standing: Arched



Back Posture Walking: Arched

LOCOMOTION SCORE

4

Clinical Description:

LAME

Description: Arched back standing and walking. Favouring one or more limbs but can still bear some weight on them. Sinking of the dew-claws is evident in the limb opposite to the affected limb.



Back Posture Standing: Arched



Back Posture Walking: Arched

LOCOMOTION SCORE

5

Clinical Description:

SEVERELY LAME

Description: Pronounced arching of back. Reluctant to move, with almost complete weight transfer off the affected limb.



Back Posture Standing: Arched



Back Posture Walking: Arched






*Adapted from Sprecher, D.J.; Hostetler, D.E.; Karsawa, J.B. 1987. Theriogenology 47:1179-1187 and contribution from Cook, N.B. University of Wisconsin.

DairyNZ also have lameness scoring guidance for cattle on their website:

http://www.dairynz.co.nz/page/pageid/2145876673/Lameness_Scoring

Goats

This chart can be used broadly for all breeds of goats farmed in New Zealand, although it is useful to note that dairy goats in general tend to be leaner than meat goats. The use of body condition scores (BCS) is less accurate for assessing kids and growing goats. Body condition scoring is based on palpation of the spine, pelvis and rump of live animals. The simple scoring system varies from score 0 (emaciated) to 5 (obese). Visual assessment of body condition of goats can be difficult where the coat is long e.g. in Angoras in full fleece. A long fleece can disguise the actual appearance of the pelvis, ribs and spine, while a short coat can make the animal's appearance more irregular and highlight these areas. The only reliable method of assessing animal body condition is by palpation of the ribs, spine, pelvis and rump.

Condition Score		Description
0 (Emaciated)		No internal or external fat reserves
1 (Poor)		Loin No muscle on edges of transverse process, bones very sharp, thin skin. Vertebral angle has little muscle and is very concave. Spinous processes very prominent with no muscle in between.
	Rump	Sharp outline visible; no muscle between skin and bones
	Pins	Very sharp, no padding
2 (Thin)		Loin Muscle extends to the edges of transverse process, spacing can be felt between the vertebral processes, thin skin
	Rump	Outline slightly contoured; light padding but bones still somewhat prominent and very easy to feel
	Pins	Sharp, little padding
3 (Good)		Loin Muscle and subcutaneous fat covers edges of vertebral process; individual bones are somewhat distinct
	Rump	Smooth, without signs of fat; pelvic bones and spine are distinct
	Pins	Slight pressure needed to feel the pin bones
4 (Fat)		Loin Vertebral processes indistinct and firm pressure needed to feel them. Vertebral angle rounded but not yet bulging over spinous processes. Spinous process spacing difficult to detect; spine felt as a hard line
	Rump	Heavily padded with fat; bones can only be felt with firm pressure
	Pins	Heavily padded with fat and firm pressure needed to feel them
5 (Obese)		Loin Edge of vertebral processes and spacing between too fat to feel bones. Vertebral angle bulges over the level of the spinous processes.
	Rump	Spine lies in the centre of a groove of fat
	Pins	Buried in fat, bones very indistinct Buried in fat, hard to locate